



“What is on my ear?”

Benjamin Barankin, MD, FRCPC

A 75-year-old male with significant sun damage on his face and neck presents with a purple papule on his ear, which he noticed soon after his cataract surgery. He has a history of diabetes and high BP which is well-controlled.

1. What is the most likely diagnosis?

- Melanoma
- Pigmented basal cell carcinoma
- Cherry angioma
- Venous lake

2. What is the most common location for this lesion?

- Nose
- Ear
- Lower lip
- Upper lip
- B and C

3. How could you manage this lesion?

- Educate and reassure as to benign nature
- Electrosurgery
- Excision
- Laser
- All of the above

A venous lake is an asymptomatic vascular ectasia/dilatation likely with vascular thrombosis exacerbated by sun damage. These papules present as dark blue-to-purple papules which are compressible and soft. Most commonly, they are noted on the lower lip and ears of the

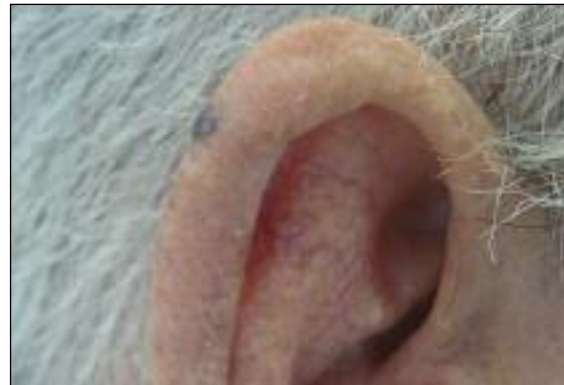


Figure 1. Purple papule on the ear.

elderly. It is important to differentiate venous lakes from melanoma and pigmented basal cell cancer. While most persons affected are male, females are more likely to present for treatment. If the diagnosis is in doubt, a biopsy can be performed.

Management of these lesions includes:

- excision,
- cryosurgery, or
- electrosurgery.

Cosmetically, Nd:YAG laser has been shown to give excellent results with just one treatment. Intense pulsed light and CO₂ lasers have also shown efficacy. 

Answers: 1-d; 2-e; 3-e

Dr. Barankin is a Dermatologist practicing in Toronto, Ontario.